

## What does the water inside the brain tell us? Diffusion tensor imaging

Niyazi Acer<sup>1\*</sup>, Mehmet Sait Dundar<sup>2</sup> and Serap Bastepe-Gray<sup>3</sup>

### Abstract

The brain consist of about 75 percent water. Diffusion tensor imaging (DTI) is an advanced magnetic resonance (MR) technique imaging that has been developed for diagnostic and research in medicine. It can be use DTI tractography to better understand degenerating axons of white matter lesions in some neurological diseases such as MS, AD, trauma, cerebral ischemia, epilepsy, brain tumors and metabolic disorders.

**Keywords:** Diffusion tensor imaging, white matter lesions

<sup>1</sup>Erciyes University Faculty of Medicine, Department of Anatomy, Kayseri, Turkey

<sup>2</sup>Abdullah Gul University, Faculty of Engineering, Electrical and Computer Engineering, Kayseri, Turkey

<sup>3</sup>Johns Hopkins University, The Peabody Conservatory, Baltimore, Maryland, USA

\*Corresponding author: N. Acer  
E-mail: acerniyazi@yahoo.com

DOI: 10.2478/ebtj-2018-0047

The brain consist of about 75 percent water. The brain is composed of 40% gray and 60% white matter. The white matter is made of axons and dendrites that the neurons use to transmit signals. Function of white matter is to give a pathway for connecting the different areas of the brain (1).

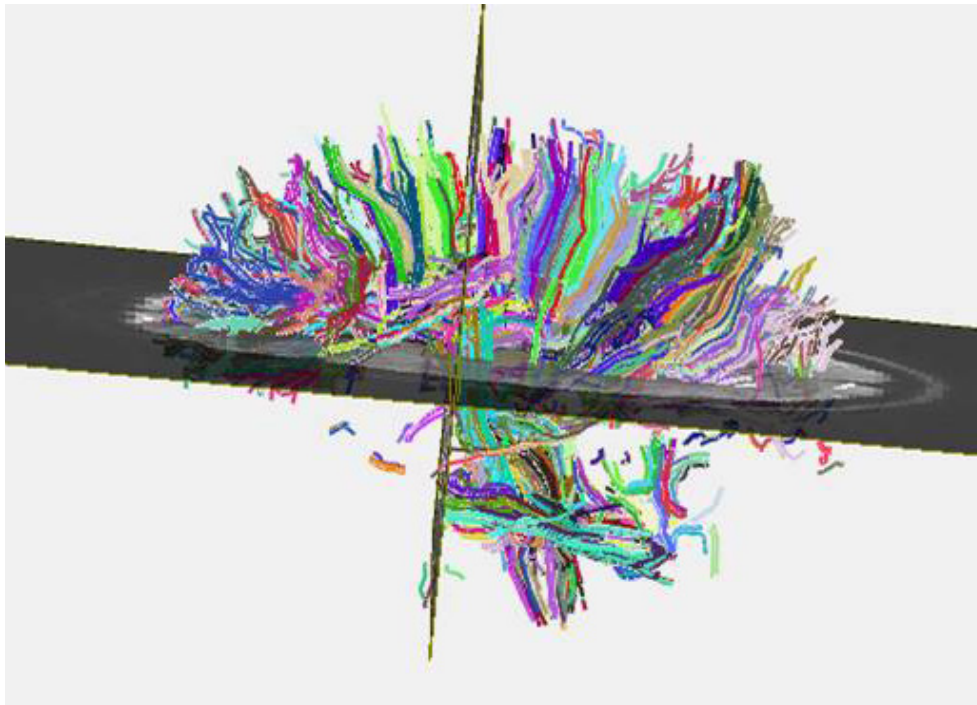
Diffusion tensor imaging (DTI) is an advanced magnetic resonance (MR) technique imaging that has been developed for diagnostic and research in medicine. DTI measures the diffusion of water molecules that helps to investigate the fiber architecture of the brain white matter (2). Utility for the evaluation of suspected acute ischemic stroke was developed DTI in neuroradiology during the early 1990s (3).

Also, DTI measures anisotropy per pixel and provides the directional information relevant fiber tracking in vivo using tractography (4). The water molecules are moving in a specific direction and molecular mobility is not equal for all directions. This is referred to as anisotropy, whereas isotropic diffusion is when the molecular motion is equal and unconstrained in all directions (5, 6). A diffusion tensor is defined in a  $3 \times 3$  matrix that is calculated for each voxel. This tensor can fully define the correlation between these directions and the molecular mobility along each direction. To get this directional information, additional diffusion-weighted images along several gradient directions have to be taken using diffusion-sensitized MR imaging pulse sequences (5). DTI sequences involve in spin-echo sequence with single-shot, echo-planar acquisition.

The most common parameters derived from the diffusion tensor in postprocessing of the diffusion-weighted images are the fractional anisotropy (FA), mean diffusivity (MD), axial diffusivity (AD) and radial diffusivity (RD) (5, 7).

FA represents the difference of the tensor ellipsoid's shape from that of a perfect sphere and is the most widely used anisotropy measure. As a measure of the degree of the diffusion anisotropy for FA values range from 1 to 0. The MD is an overall measure of the diffusion in a voxel, AD is a measure of diffusivity along the main axis and RD is the average diffusivity of the two minor axes (8).

3D DTI fiber tracking is used for quantitatively assessing the microstructure of a specific white matter tract. Diffusion metric image maps such as FA, Apparent diffusion co-



**Figure 1.** White matter organization using DtiStudio.

efficient (ADC), and the eigenvalues are naturally registered to the resultant DTI fiber tracks (8).

Several software tools have been developed recently to automatically obtain diffusion parameter values of white matter tracts using different strategies such as the SPM, Freesurfer, FSL etc.

There are lots of DTI tractography algorithms that have been reported to date, and every year many more are presented. Mori and van Zijl (2002) reported a basic overview of deterministic streamline fiber tracking methods. However, for three-dimensional tract reconstruction can use the Fiber Assignment by Continuous Tracking (FACT) algorithm that based on the multiple ROI “virtual dissection” technique for isolating specific anatomic pathways, remains the most popular approach for both clinical and scientific applications (9, 10, 11). For fiber tractography can perform using DTIStudio (13). The seed areas used for selective fiber tractography should select on 3D DTI color images (Fig 1).

There are two main analytical methods voxel-based analysis (VBA) and region-of-interest (ROI) analysis that can be applied in the investigation of DTI measurements. Many recently published studies use the specific ROIs approach however the subjectivity of the choice and placement of ROIs brings some limitation for this method (13).

Voxel-based analysis (VBA) methods based on statistical parametric mapping, popular for unbiased whole-brain analysis of DTI data, have also been published (8, 13, 15). VBA provides a complete overview of white matter integrity in the brain and allows for whole-brain analysis. Tract-based spatial statistics (TBSS) is similar to VBA in that an automated method of detecting group-wise changes in diffusion metrics from the white matter organisation of the whole brain (8, 14).

Using these software, researchers studied some common neurologic and psychiatric brain disorders including attention deficit hyperactivity disorder, schizophrenia, depression, Alzheimer’s disease (AD), Parkinson disease, and multiple sclerosis (MS).

DTI is popular imaging modality and an increasingly prevalent method that has been used to numerous scientific studies and clinical problems advancing the scientific understanding of many neurologic and psychiatric disorders. Combining DTI and fiber tractography have been applied clinically for the pre-surgical mapping of eloquent white matter tracts before intracranial tumor resections.

Utility of DTI includes investigation of age-related degeneration, diffuse axonal injury and demyelinated lesions, as well as various other brain pathology. It can be use DTI tractography to better understand degenerating axons of white matter lesions in some neurological diseases such as MS, AD, trauma, cerebral ischemia, epilepsy, brain tumors and metabolic disorders.

## References

1. Fields RD. Change in the Brain’s White Matter: The role of the brain’s white matter in active learning and memory may be underestimated. *Science* (New York, NY). 2010;330(6005): 768–769.
2. Le Bihan D, Mangin JF, Poupon C. et al: Diffusion tensor imaging: concepts and applications. *J Magn Reson Imaging* 2001;13:534-546.
3. Mukherjee P, Berman JI, Chung SW, Hess CP, Henry RG. Diffusion tensor MR imaging and fiber tractography: theoretic underpinnings. *AJNR Am J Neuroradiol*. 2008a;29(4):632-41.
4. Bammer R, Acar B, Moseley ME. In vivo MR tractography using diffusion imaging. *Eur J Radiol*. 2003;45(3):223-34.
5. de Figueiredo EH, Borgonovi AF, Doring TM. Basic concepts of MR imaging, diffusion MR imaging, and diffusion tensor imaging.

- Magn Reson Imaging Clin N Am. 2011;19(1):1-22.
6. Sundgren PC, Dong Q, Gómez-Hassan D, Mukherji SK, Maly P, Welsh R. Diffusion tensor imaging of the brain: review of clinical applications. *Neuroradiology*. 2004;46(5):339-50.
  7. Huisman TAGM. Diffusion-weighted and diffusion tensor imaging of the brain, made easy. *Cancer Imaging*. 2010;10:163-171.
  8. Mukherjee P, Chung SW, Berman JI, Hess CP, Henry RG. Diffusion tensor MR imaging and fiber tractography: technical considerations. *AJNR Am J Neuroradiol*. 2008b;29(5):843-52.
  9. Mori S, van Zijl PC. Fiber tracking: principles and strategies—a technical review. *NMR Biomed* 2002;15:468–80
  10. Conturo TE, Lori NF, Cull TS, et al. Tracking neuronal fiber pathways in the living human brain. *Proc Natl Acad Sci USA* 1999;96:10422–27
  11. Catani M, Howard RJ, Pajevic S, et al. Virtual in vivo interactive dissection of white matter fasciculi in the human brain. *Neuroimage* 2002;17:77–94
  12. Acer N, Dolu N, Zararsiz G, Dogan MS, Gümüş K, Özmen S, Kara AY, Soysal H, Per H, Bilgen M. Anatomical characterization of ADHD using an atlas-based analysis: A diffusion tensor imaging study. *Eurobiotech J* 2017; 1: 46-56
  13. Acer N, Bastepe-Gray S, Sagioglu A, Gumus KZ, Degirmencioglu L, Zararsiz G, Ozic MU. Diffusion tensor and volumetric magnetic resonance imaging findings in the brains of professional musicians. *J Chem Neuroanat*. 2018;88:33-40.
  14. Smith SM, Jenkinson M, Johansen-Berg H, et al. Tract-based spatial statistics: voxelwise analysis of multi-subject diffusion data. *Neuroimage* 2006;31:1487–505
  15. Jones DK, Symms MR, Cercignani M, et al. The effect of filter size on VBM analyses of DT-MRI data. *Neuroimage* 2005;26:546–54